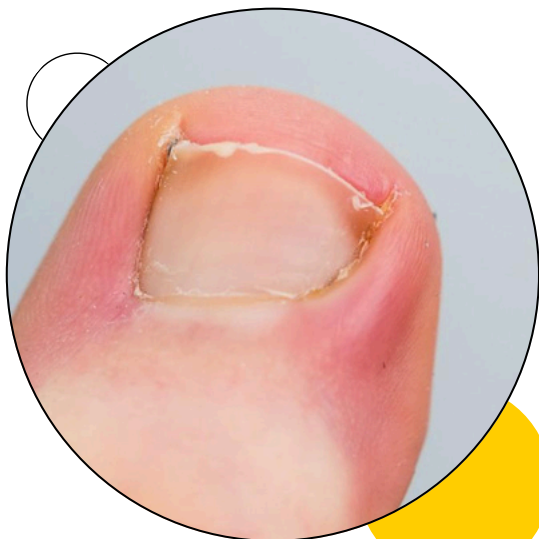

# REGENERIS

FOOT HEALTH CLINIC

089 432 6187



## INGROWN TOENAIL

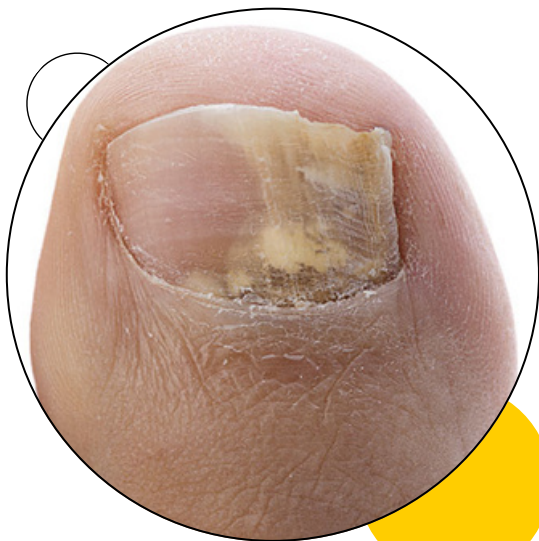Ingrown toenails are a common condition in which the corner or side of a toenail grows into the soft flesh. The result is pain, inflamed skin, swelling and, sometimes, an infection. Ingrown toenails usually affect the big toe.

[www.regenerispodiatryclinic.com](http://www.regenerispodiatryclinic.com)

# REGENERIS

FOOT HEALTH CLINIC

089 432 6187



## FUNGUS TOENAIL

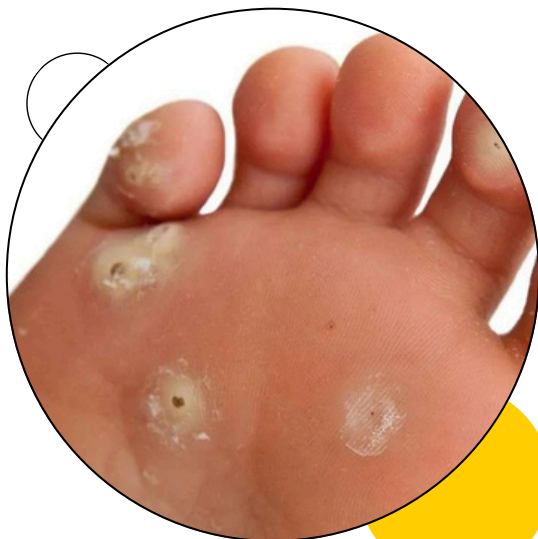Fungus toenail, known as onychomycosis, is a common fungal infection of the toenails. It causes the nail to become thickened, discolored (yellow, brown, or white), brittle, and sometimes misshapen. The infection often starts at the edge of the nail and spreads inward. It can result from exposure to fungi in warm, moist environments like locker rooms or from wearing tight shoes.

[www.regenerispodiatryclinic.com](http://www.regenerispodiatryclinic.com)

# REGENERIS

## FOOT HEALTH CLINIC

089 432 6187



## PLANTAR WARTS

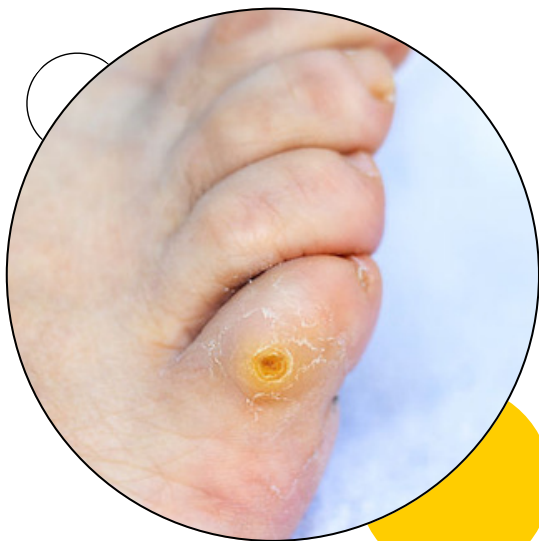Plantar warts are small, rough growths that appear on the soles of the feet, caused by the human papillomavirus (HPV). They often develop in areas that bear weight, such as the heels or balls of the feet, and may grow inward due to pressure. These warts can be painful, especially when walking or standing. They may have tiny black dots on the surface (clotted blood vessels) and are typically flat with a thickened layer of skin over them.

[www.regenerispodiatryclinic.com](http://www.regenerispodiatryclinic.com)

# REGENERIS

FOOT HEALTH CLINIC

089 432 6187



## FOOT CORN

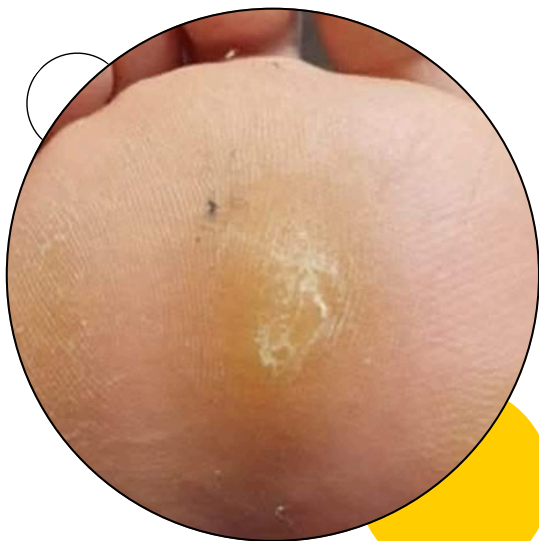A foot corn is a small, thickened area of skin caused by repeated pressure or friction, usually from tight shoes. Corns are smaller and deeper than calluses and have a hard center surrounded by swollen skin. They can be painful when pressed. Hard corns often form on the top of the toes or the outer edge of the small toe. Soft corns tend to form between the toes.

[www.regenerispodiatryclinic.com](http://www.regenerispodiatryclinic.com)

# REGENERIS

FOOT HEALTH CLINIC

089 432 6187



## PLANTAR CALLUS

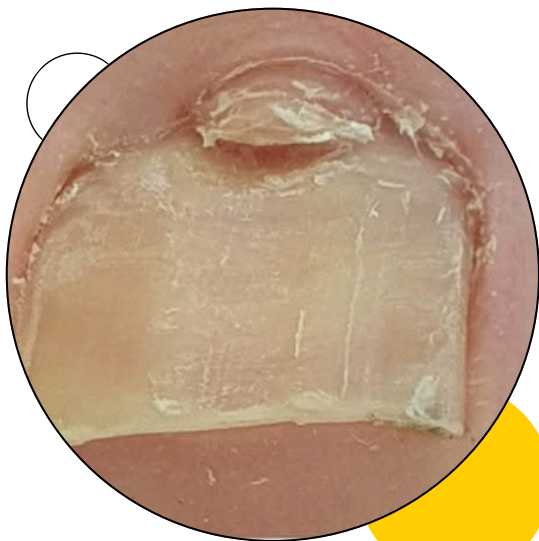
A plantar callus is a thickened, hardened area of skin that forms on the sole of the foot, usually under the heel or ball, due to repeated pressure or friction. Calluses are rarely painful and tend to develop on pressure spots, such as the heels, the balls of the feet, the palms and the knees. They may vary in size and shape and are often larger than corns.

[www.regenerispodiatryclinic.com](http://www.regenerispodiatryclinic.com)

# REGENERIS

FOOT HEALTH CLINIC

089 432 6187



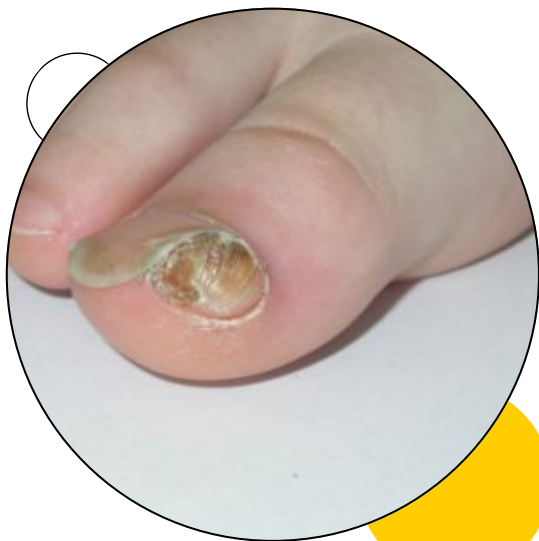## PERIUNGUAL FIBROMAS

Periungual fibromas are small, soft, and compressible papules typically found adjacent to the proximal or lateral nail folds. Periungual fibromas may place excessive pressure on the nail matrix, resulting in the potential for extensive nail pathologic conditions and pain.

# REGENERIS

FOOT HEALTH CLINIC

089 432 6187



## SUBUNGUAL EXOSTOSIS

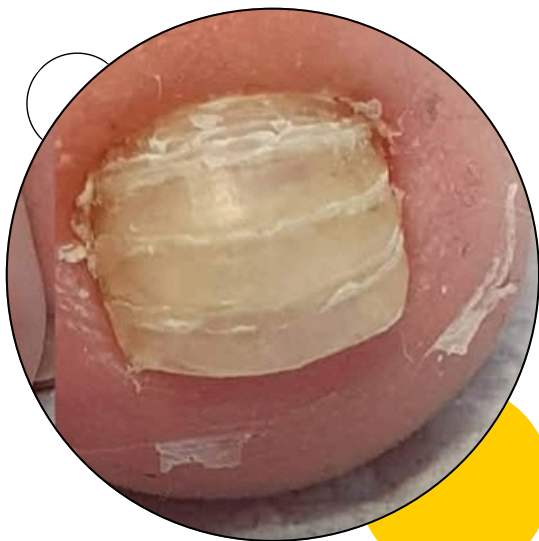
Subungual exostosis is a type of non-cancerous bone tumor of the chondrogenic type, and consists of bone and cartilage. It usually projects from the upper surface of the big toe underlying the nailbed, giving rise to a painful swelling that destroys the nail. Subsequent ulceration and infection may occur.

[www.regenerispodiatryclinic.com](http://www.regenerispodiatryclinic.com)

# REGENERIS

FOOT HEALTH CLINIC

089 432 6187



## RETRONYCHIA

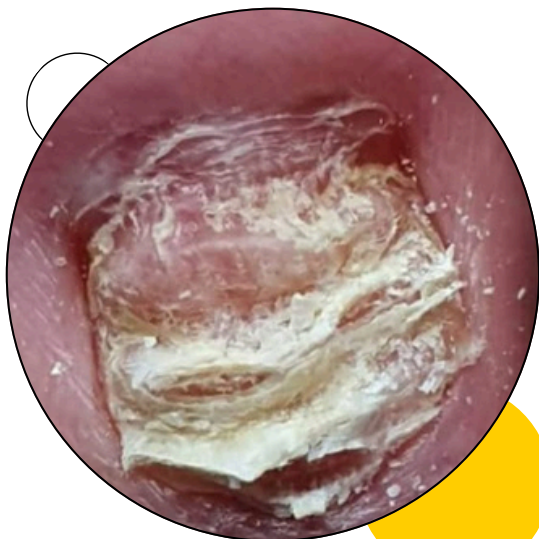
Retronychia is a nail disorder where the proximal nail plate (the part of the nail closest to the cuticle) ingrows into the proximal nail fold (the skin around the nail base). This ingrowth can lead to multiple nail plates stacking up beneath the fold. It's often caused by trauma or repetitive microtrauma to the nail, like from wearing tight shoes.

[www.regenerispodiatryclinic.com](http://www.regenerispodiatryclinic.com)

# REGENERIS

FOOT HEALTH CLINIC

089 432 6187



## PARAKERATOSIS POSTULOS

Parakeratosis pustulosa describes a deformed fingernail or toenail surrounded by red, often scaly skin.

It often starts with reddening of the skin under the free margin of the nail or toenail. The redness later extends down to the nail fold resulting in swelling and loss of the cuticle. Thickened skin pushes up and deforms the nail plate.

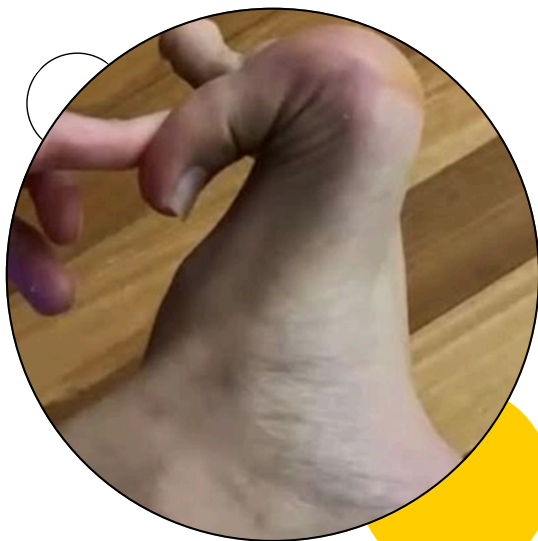Parakeratosis pustulosa is not itchy, but it may be a little painful.

[www.regenerispodiatryclinic.com](http://www.regenerispodiatryclinic.com)

# REGENERIS

FOOT HEALTH CLINIC

089 432 6187



## HYPERMOBILITY

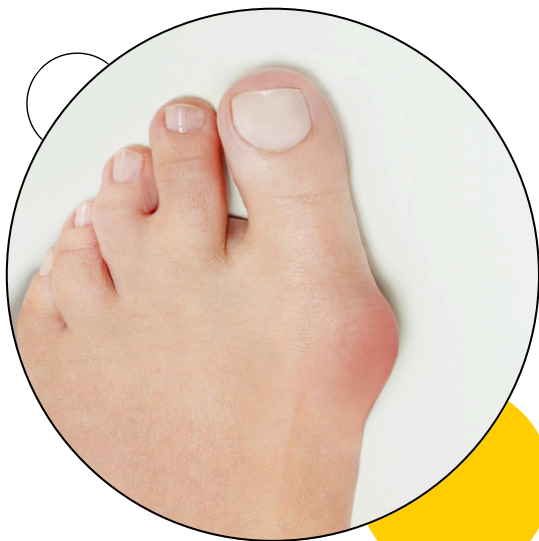Hypermobility of the toes means the joints in the toes are more flexible than usual, allowing them to move beyond their normal range of motion. This can be a symptom of joint hypermobility syndrome, also known as hypermobility spectrum disorder, or it can be a separate condition in some cases

[www.regenerispodiatryclinic.com](http://www.regenerispodiatryclinic.com)

# REGENERIS

FOOT HEALTH CLINIC

089 432 6187



## BUNION (HALLUX VALGUS)

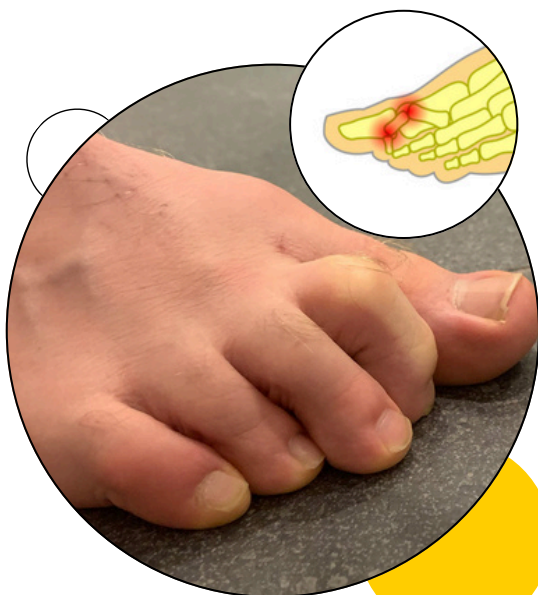A bunion, also known as hallux valgus, is a deformity of the MTP joint connecting the big toe to the foot. The big toe often bends towards the other toes and the joint becomes red and painful. The onset of bunions is typically gradual. Complications may include bursitis or arthritis.

[www.regenerispodiatryclinic.com](http://www.regenerispodiatryclinic.com)

# REGENERIS

FOOT HEALTH CLINIC

089 432 6187



## CLAW TOE

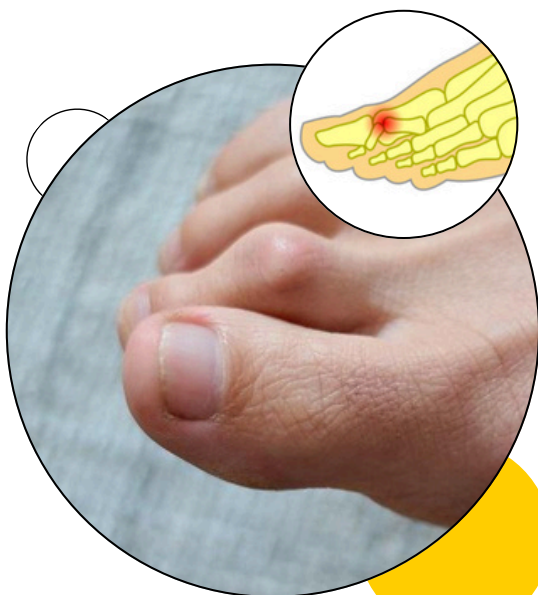Clawed toes, also known as claw toe, is a foot deformity where the toes are bent into a claw-like position, often at the middle and end joints. This usually occurs in the smaller toes (2nd, 3rd, 4th, and 5th), leaving the big toe relatively unaffected. The condition can be caused by muscle imbalances, high arches, or neurological issues, and can lead to pain, corns, and calluses.

[www.regenerispodiatryclinic.com](http://www.regenerispodiatryclinic.com)

# REGENERIS

FOOT HEALTH CLINIC

089 432 6187



## HAMMER TOE

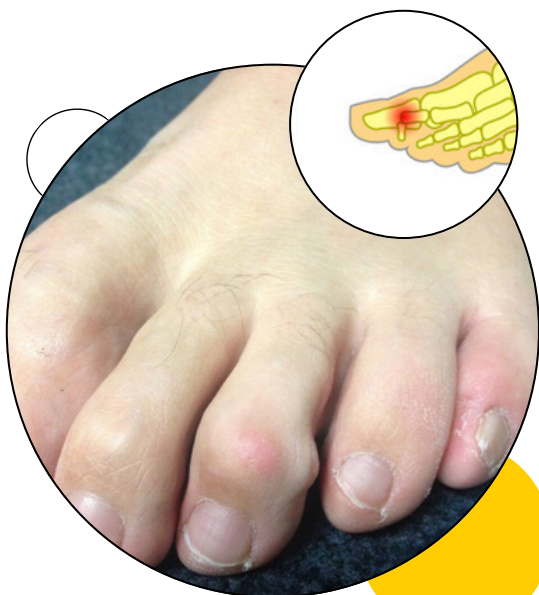A hammer toe, hammertoe or contracted toe is a deformity of the muscles and ligaments of the proximal interphalangeal joint of the second, third, fourth, or fifth toe, bending it into a shape resembling a hammer

[www.regenerispodiatryclinic.com](http://www.regenerispodiatryclinic.com)

# REGENERIS

FOOT HEALTH CLINIC

089 432 6187



## MALLET TOE

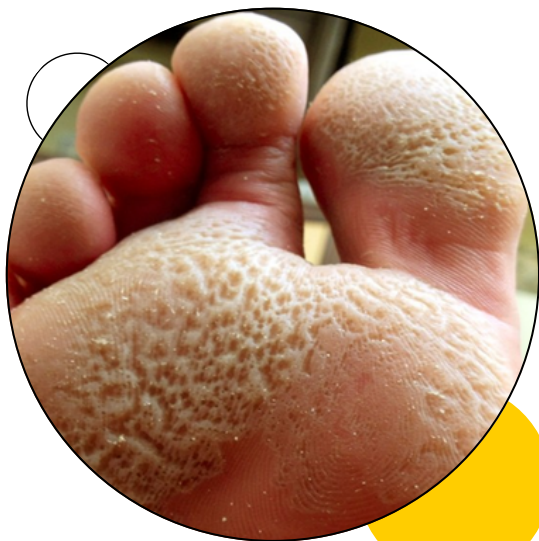A mallet toe has an abnormal bend or buckle in the top toe joint, nearest to the toenail. This causes the tip of the toe to curl or point down instead of lying flat. Mallet toe most often affects your second toe, next to your big toe, because this toe is often the longest. But it can also affect your third or fourth toe

[www.regenerispodiatryclinic.com](http://www.regenerispodiatryclinic.com)

# REGENERIS

FOOT HEALTH CLINIC

089 432 6187



## PITTED KERATOSIS

Pitted keratolysis, also known as keratolysis plantare sulcatum or ringed keratolysis, is a bacterial infection of the skin that commonly affects the feet.

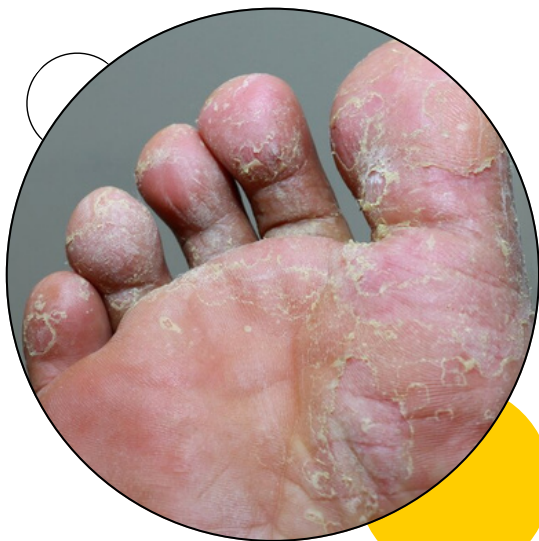It typically occurs on the areas of feet that are subject to high pressure, such as the heels and the balls of the feet. It causes clusters of small 'pits' in the skin which are usually approximately 1-3mm in size. Sometimes, these clusters can join together to form a larger pit or crater in the skin.

[www.regenerispodiatryclinic.com](http://www.regenerispodiatryclinic.com)

# REGENERIS

FOOT HEALTH CLINIC

089 432 6187



## ATHLETE'S FOOT

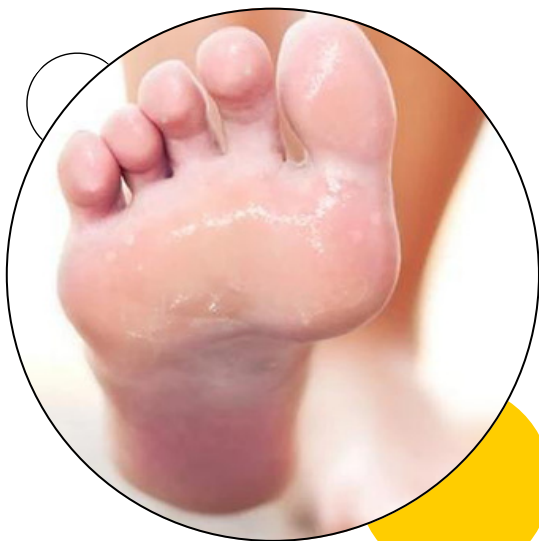Athlete's foot, known medically as tinea pedis, is a common skin infection of the feet caused by a fungus. Signs and symptoms often include itching, scaling, cracking and redness. In rare cases the skin may blister. Athlete's foot fungus may infect any part of the foot, but most often grows between the toes

[www.regenerispodiatryclinic.com](http://www.regenerispodiatryclinic.com)

# REGENERIS

FOOT HEALTH CLINIC

089 432 6187



## HYPERHIDROSIS

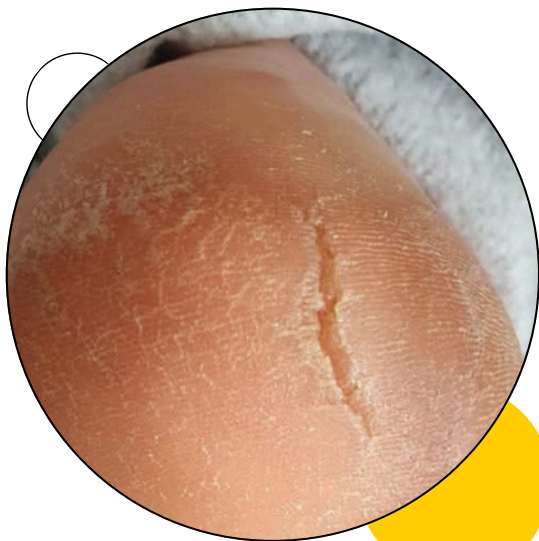Hyperhidrosis, also called excessive sweating, is a medical condition that affects different body areas including the feet

[www.regenerispodiatryclinic.com](http://www.regenerispodiatryclinic.com)

# REGENERIS

FOOT HEALTH CLINIC

089 432 6187



## CRACKED HEELS

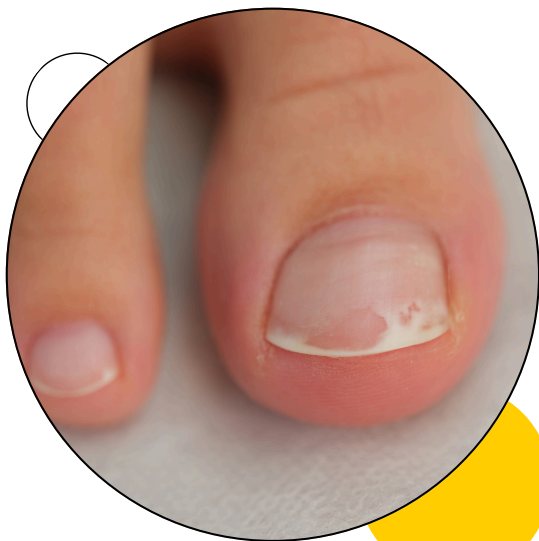Cracked heels, also known as heel fissures, are a common condition where the skin on the heels becomes dry, thickened, and cracked, often causing pain and discomfort. The primary cause is dry skin, which can be exacerbated by factors like prolonged standing or walking barefoot.

[www.regenerispodiatryclinic.com](http://www.regenerispodiatryclinic.com)

# REGENERIS

FOOT HEALTH CLINIC

089 432 6187



## ONYCHOLYSIS

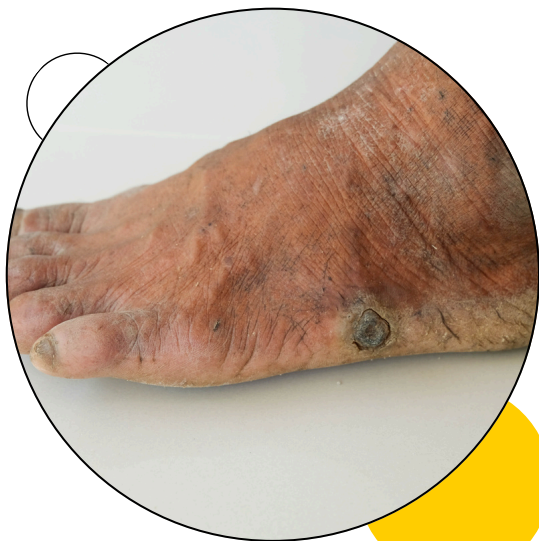Onycholysis, a nail condition where the nail separates from its nail bed, can affect both fingernails and toenails. It's often triggered by injury, but other causes include fungal infections, certain medications, and psoriasis. The affected nail may appear white, discolored, or thickened. Onycholysis (nail separation) can occur after using hybrid gel nail polishes (like Shellac, Gelish, etc.).

[www.regenerispodiatryclinic.com](http://www.regenerispodiatryclinic.com)

# REGENERIS

FOOT HEALTH CLINIC

089 432 6187



## DIABETIC FOOT

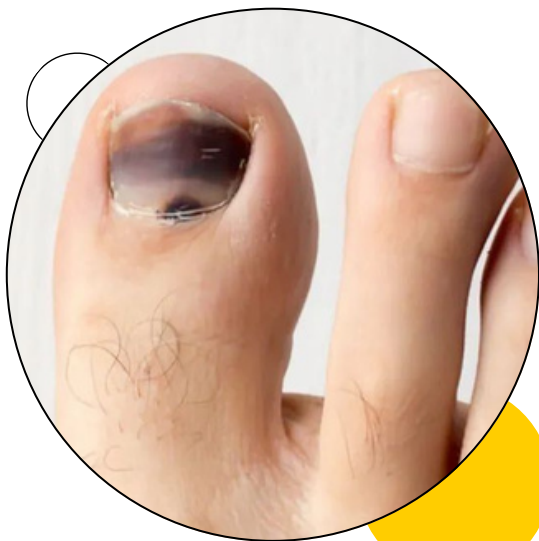A diabetic foot disease is any condition that results directly from peripheral artery disease or sensory neuropathy affecting the feet of people living with diabetes. Diabetic foot conditions can be acute or chronic complications of diabetes

[www.regenerispodiatryclinic.com](http://www.regenerispodiatryclinic.com)

# REGENERIS

FOOT HEALTH CLINIC

089 432 6187



## SUBUNGUAL HEMATOMA

Toenail trauma, often resulting in a subungual hematoma (bruised toenail), can occur from various causes like heavy objects, running, or stubbing the toe. Symptoms include pain, throbbing, discoloration (blueish-black), and potentially nail separation.

[www.regenerispodiatryclinic.com](http://www.regenerispodiatryclinic.com)